


REPORT

Patient Name	: Mrs. NANCY	Reg. No.	: 00261812270028
Age and Sex	: 27 Yrs / Female	PCC Code	: PCL-HR-094
Referring Doctor	: NA	Sample Drawn Date	: 27-Dec-2018 02:00 PM
Referring Customer	: N/A	Registration Date	: 29-Dec-2018 05:52 AM
Vial ID	: H1857463	Report Date	: 11-Jan-2019 09:40 AM
Sample Type	: WB-Sodium Heparin	Report Status	: Final Report
Client Address	: 6349/1, Nicholson Road, Ambala Cantt, Haryana		

CYTOGENETICS
Chromosomal Analysis- Blood

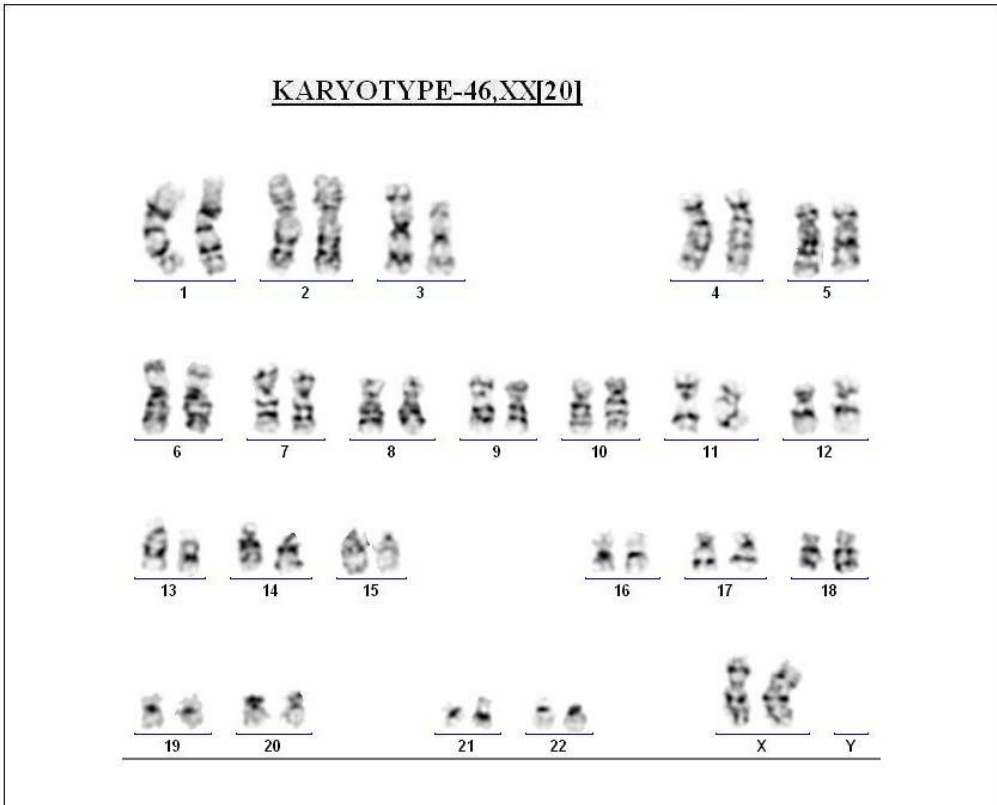
CYTOGENETICS NUMBER	PCL/CG/6175/18
CLINICAL HISTORY	-
NO OF CELLS SCORED	20
NO OF METAPHASES ANALYZED	20
NO OF METAPHASES KARYOTYPED	10
BANDING METHOD	GTG Banding
BAND RESOLUTION	550
KARYOTYPE (ISCN-2016)	46,XX[20]
DIAGNOSIS	Normal Female Karyotype.
INTERPRETATION	Cytogenetic analysis of PHA stimulated peripheral blood lymphocytes revealed a Normal Female Karyotype without any structural or numerical chromosome abnormalities.
RECOMMENDATIONS	-



DR. KANAKADURGA K
 Ph.D GENETICS

REPORT

Patient Name	: Mrs. NANCY	Reg. No.	: 00261812270028
Age and Sex	: 27 Yrs / Female	PCC Code	: PCL-HR-094
Referring Doctor	: NA	Sample Drawn Date	: 27-Dec-2018 02:00 PM
Referring Customer	: N/A	Registration Date	: 29-Dec-2018 05:52 AM
Vial ID	: H1857463	Report Date	: 11-Jan-2019 09:40 AM
Sample Type	: WB-Sodium Heparin	Report Status	: Final Report
Client Address	: 6349/1, Nicholson Road, Ambala Cantt, Haryana		

CYTOGENETICS



re[®]
UTION

Correlate Clinically.

Laboratory is NABL Accredited

*** End Of Report ***



K. Kanakadurga
DR. KANAKADURGA K
Ph.D GENETICS