


REPORT

Patient Name	: Mr. VAIBHAV	Reg. No.	: 00261901160026
Age and Sex	: 30 Yrs / Male	PCC Code	: PCL-HR-094
Referring Doctor	: NA	Sample Drawn Date	: 15-Jan-2019 11:00 AM
Referring Customer	: KOS LAB AMBALA	Registration Date	: 18-Jan-2019 06:34 AM
Vial ID	: H1857448	Report Date	: 29-Jan-2019 10:24 AM
Sample Type	: WB-Sodium Heparin	Report Status	: Final Report
Client Address	: 6349/1, Nicholson Road, Ambala Cantt, Haryana		

CYTOGENETICS
Chromosomal Analysis- Blood

CYTOGENETICS NUMBER	PCL/CG/0171/19
CLINICAL HISTORY	-
NO OF CELLS SCORED	20
NO OF METAPHASES ANALYZED	20
NO OF METAPHASES KARYOTYPED	10
BANDING METHOD	GTG Banding
BAND RESOLUTION	550
KARYOTYPE (ISCN-2016)	46,XY[20]
DIAGNOSIS	Normal Male Karyotype[20]
INTERPRETATION	Cytogenetic analysis of PHA stimulated peripheral blood lymphocytes revealed a Normal Male Karyotype without any structural or numerical chromosome abnormalities.
RECOMMENDATIONS	-

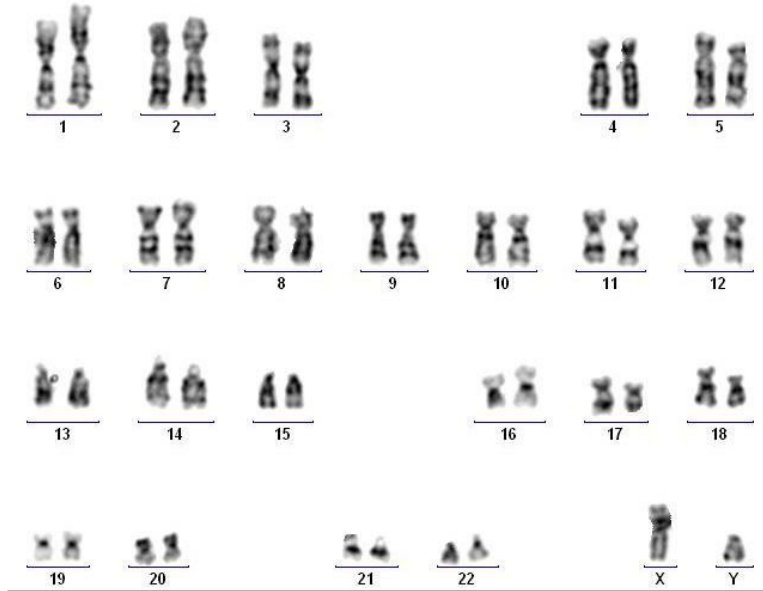


DR. KANAKADURGA K
Ph.D GENETICS

REPORT

Patient Name	: Mr. VAIBHAV	Reg. No.	: 00261901160026
Age and Sex	: 30 Yrs / Male	PCC Code	: PCL-HR-094
Referring Doctor	: NA	Sample Drawn Date	: 15-Jan-2019 11:00 AM
Referring Customer	: KOS LAB AMBALA	Registration Date	: 18-Jan-2019 06:34 AM
Vial ID	: H1857448	Report Date	: 29-Jan-2019 10:24 AM
Sample Type	: WB-Sodium Heparin	Report Status	: Final Report
Client Address	: 6349/1, Nicholson Road, Ambala Cantt, Haryana		

CYTOGENETICS

KARYOTYPE-46,XY[20]



re®
UTION

Correlate Clinically.

Laboratory is NABL Accredited

*** End Of Report ***



K. Kanakadurga
DR. KANAKADURGA K
Ph.D GENETICS